

EFFECTIVE MANAGEMENT OF MENIÈRE & VESTIBULAR DISORDERS WITH PHOTO-BIOSTIMULATION LIGHT LASER.

Eugenio Hack, MD¹; Joaquín Prósper, AuD²

¹ Department ENT at Rotger Clinic (Mallorca -Spain); ² Otoclinica Spain & AENORTA Asociation

ABSTRACT

Purpose:

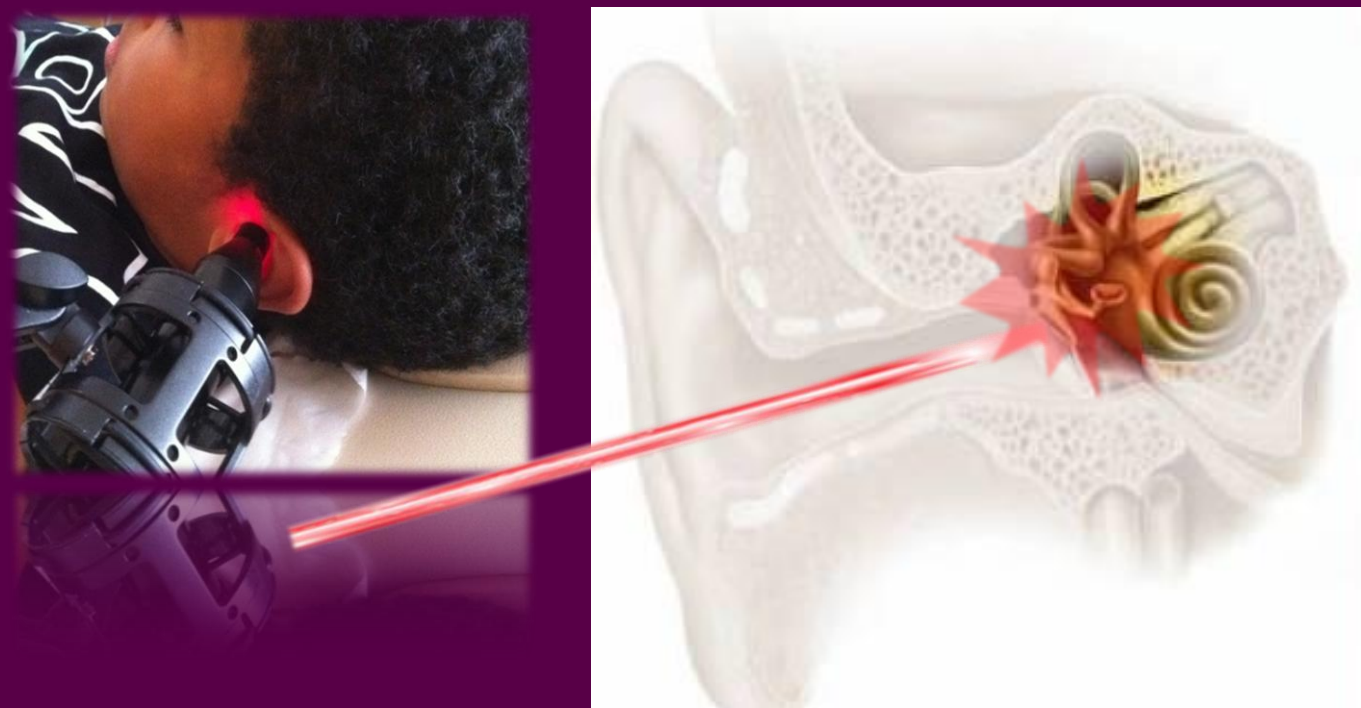
Application of laser irradiation inside the inner ear has been investigated to observe the therapeutic effectiveness in cochlear injury and vestibular dysfunction.

The positive influence of light irradiation with low level laser therapy on the treatment of vascular disorders, ischemic arteriole disease, activation of microcirculation, as well as on tissue regeneration and reparation is well known and published for several authors from Russian Medical Groups.

The aim of this study was to determine the effects and benefits on patients with Menière Disease and other vestibulopathies who received an irradiation dose into the inner ear by using a protocol of light irradiation.

Method:

A laser device with double wavelength and independent light beams were used to irradiate through the ear canal with power irradiance of 0.2 to 1.8 w/cm² at different dose rate according patient symptoms. A prospective study of a group of sixty five (65) patients who were suffering peripheral vestibular disorder were treated from 2010, January up to 2011 July in a random selection with no exclusions for other pathologies. Method of irradiation was direct beam into ear canal at 1.5 cm distance of ear drum membrane.



Results:

50 patients from the 65 were considered final group of control. According criteria of AAO-HNSF guidelines, after eighteen months of therapy, 64% of patients were classified on Category A (zero crisis) on their vertigo management and 36% were Category B.

Conclusions:

Laser irradiation with no risk for patients, can be considered both an effective and safety alternative therapy versus other treatments like corticoids via IT (Intratympanic Therapy).

INTRODUCTION

In 1981, the first experiences of "Intravenous Laser Blood Irradiation" (ILBI) by N.Menshalkin and V.S. Sergievskiy, both Russian scientists are experimented and published.

With the development of semiconductor lasers, with greater stability and power capabilities, the same applications of irradiation with light, can be done transcutaneous (TLBI) (G.Brill, 1994) with the consequent advantages of a non-invasive therapeutic technique.

- It has been shown that the ILBI (and TLBI) stimulates body's immune response, activates the erythropoiesis, and in general improves deformability of erythrocytes membrane. The irradiation of laser light has also an anti-hypoxic and analgesic effects on tissues, anti-inflammatory, vasodilator properties, spasmolytic and others which have been founded with beneficial effects on pathological processes.

- Different studies have shown that red laser light irradiation "in vitro and vivo" increases the production of nitric oxide (NO) (Klebanov G.E.et al., 1998; Klebanov G.E. et al., 2000; Maegawa Y. et al., 2000) with the consequence of increasing synthesis of GMP (Guanosine MonoPhosphato) cycle in the smooth muscle cells and platelets (Brill G.E. et to the., 1997). This mechanism may explain the vasodilatation induced by the laser, the inhibition of platelet aggregation and some other effects on the cellular levels in body (Brill A.G. et al., 2000; Yaakobi T. et al, 2001; Mirsky N. et al, 2002). There are studies of the ILBI in cellular immunity (N.F. Gamaleya et al., 1991) where the phagocyte activity of macrophages increases and, among other effects, detects an improvement of Microcirculation.

- Irradiation of blood by one or the other methods also activates other indeterminate immunity mechanisms, intensifies the bactericidal activity of blood serum and the complement system, reduces the level of c-reactive protein and produces an increase in the content of immunoglobulin's IgA, IgM and IgG in blood serum.

- The ILBI promotes the improvement of the rheological properties of blood, increasing its fluidity and activating functions of transport^{1,2} (Mi et al, 2004). This is accompanied by an increase in the level of oxygen. Arterio-venous oxygen partial pressure increase testifies the reduction of hypoxic tissues, which is a sign of normalization of tissue metabolism.

- Some earlier works of ENT specialists and others^{5,6}, (S. Tauber, L. Wilden, L.Prochazsca, M. Zazzio and more), long time ago had already announced positive results in the treatment of different hearing disorders through irradiation with laser light of the inner ear in different patients.

- The treatment of various labyrinthine disorders it's still not a medical activity exempt from uncertainty when dealing with the disease in the most efficient manner. Unfortunately in many intractable vertigo patients usual drug therapy, nor the intratympanic corticosteroid way, are able to avoid the undesirable alternative solution of vestibular ablation.

DISCUSSION

The objective of our study was to confirm photobiological effects and some molecular mechanisms formulated by Tiina Karu^{3,4}, and other photobiomodulation researchers⁶. Time ago Blood Irradiation has been used for many healing process.

Many of the disorders of the inner ear, sudden hearing loss, vestibular diseases and peripheral dizziness, Hyperacusis, etc., are the result of a possible vascular alteration or degradation of endocochlear homeostasis. Multiple proteins and other molecules, connexins, Fibrocytes, genes are involved in the vascularization of the *stria vascularis* and spiral ligament are fundamental in the ion homeostasis by the cochlear fluids and recycling the K⁺.

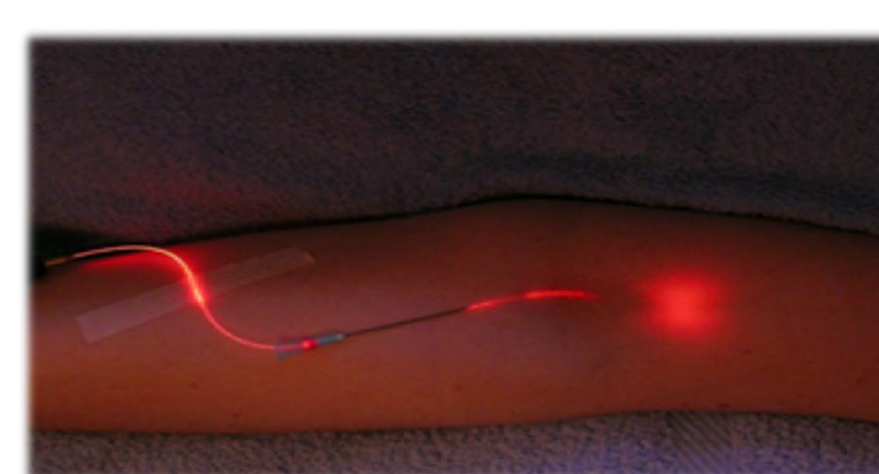
It is known that the photo-biological effects observed at the cellular level differ from one another^{3,4} (Karu T., 1989, 2007), depending on the type of laser, its wavelength, power output, fluence or dose per unit of surface, creep, or pattern of the doses, etc. In our experience, two lasers of semiconductor diode, emitting in the visible red and infrared spectrum, with 650 nm and 808 nm wavelength, have been used to radiate a group of patients with different vestibular pathologies.

The majority of these patients had peripheral vertigo and other auditory symptoms as aural pressure, tinnitus, hearing loss and other like hyperacusis as dysfunctions companions. The scope and amount of radiation that reaches inside of the cochlea were already tested⁵ by Tauber, S. in 2001 and about these works of transferred energy, then the Protocol was adjusted in their dose, particularly to each patient.

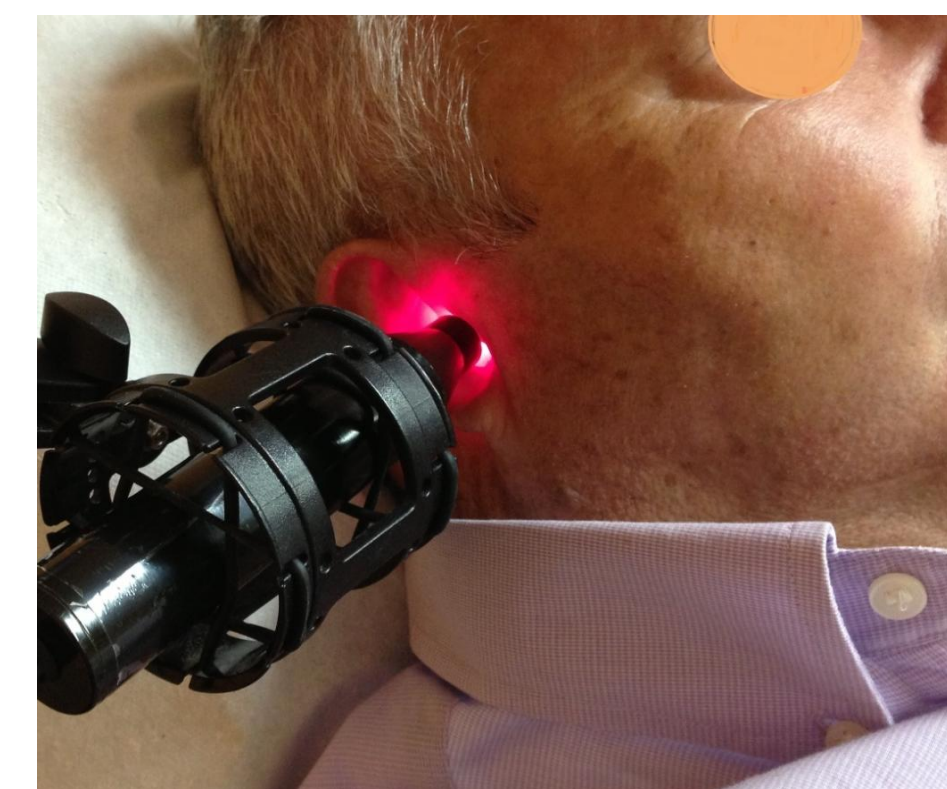
METHOD AND MATERIALS

Photo-Biostimulation Laser Data &Therapy protocol

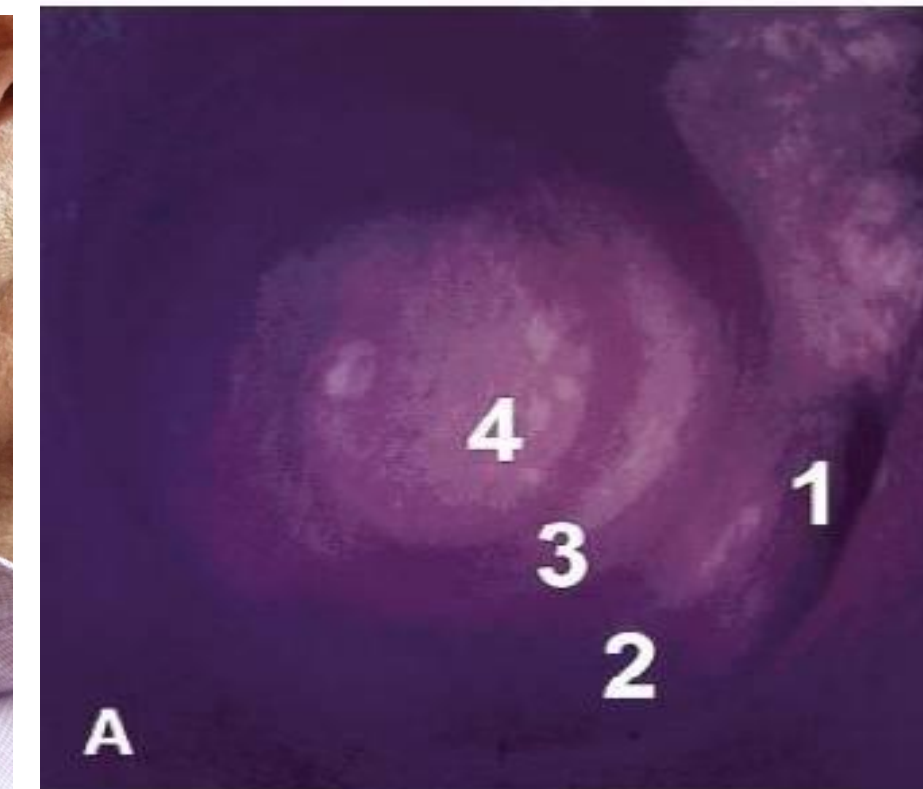
- Two types of semiconductor lasers emitting 650nm and 808nm light wavelength
- Regulated maximum output power did not exceed the 100 mW (650 nm) and 300 mW (808 nm).
- The intensity of energy applied, variable according to the disorder and each patient, did not exceed 1.8 w/cm² for 808 nm and 0,20 w/cm² for 650 nm laser.
- The laser probe is introduced into the ear canal, placing it at a distance approximately 15-17 mm of the eardrum.
- The evaluation of therapy and their effects, for all patients, were check-in after a standard protocol of 12 sessions, twice a week, in 6-7 weeks of treatment.
- In any case, the photo-thermal effect is used. The heat does not act and does not explain the effects and benefits of the photo-biostimulation.



"IntraVenous Laser Blood Irradiation" (ILBI)



View of patient with Laser Photo-Therapy



Tauber S. et al., 2001.- copyright S.Tauber⁵, Munich University
Micro-photo (retrocochlear endoscope)

Photo (A): 1 oval window, 2, 3 y 4, basal, media y upper spiral

Photo (B): cochlea irradiated by red laser light of 635nm. Laser was applied through external ear canal about 15 mm of the ear drum.

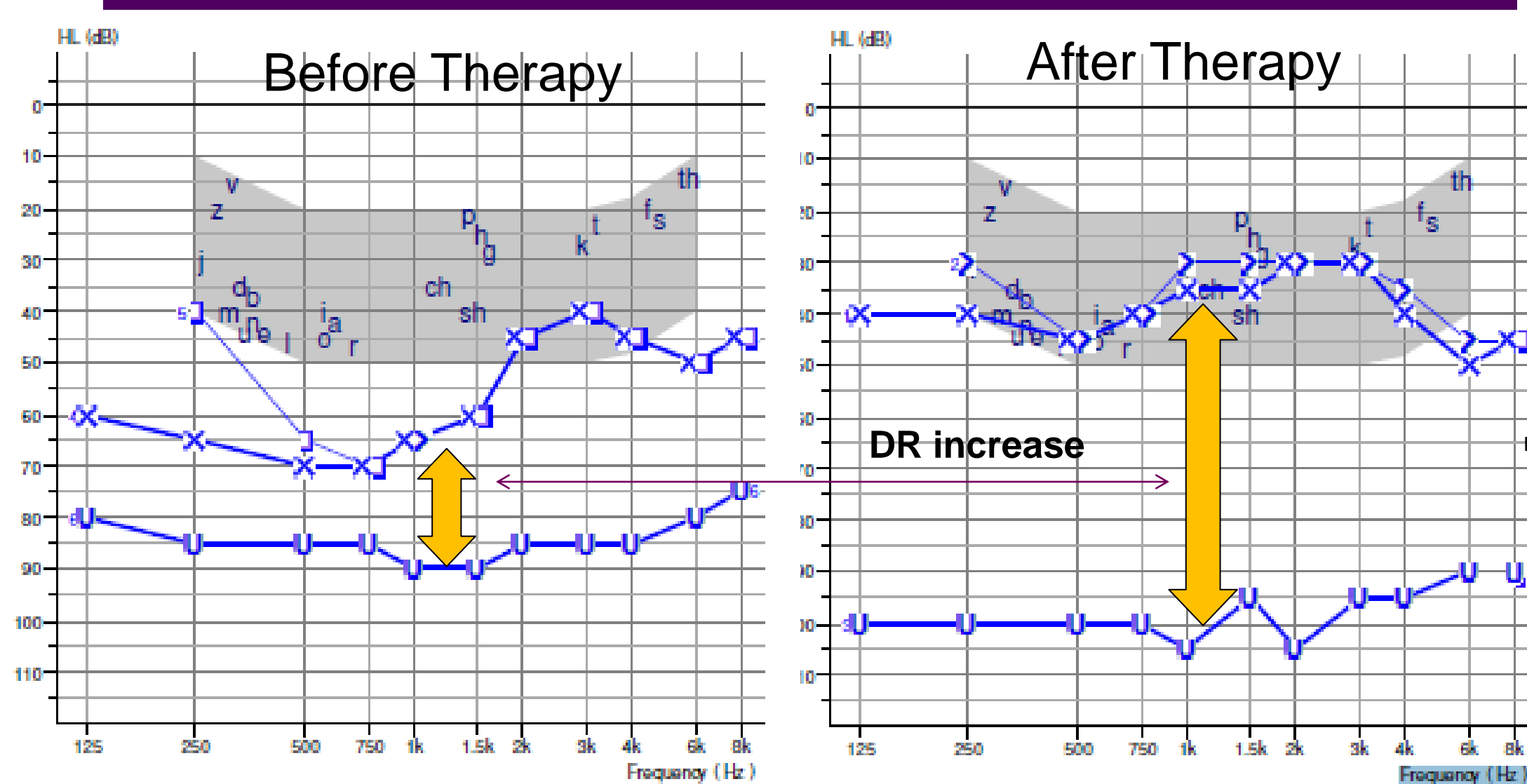
Graphs show a success patient comparing audiometric range before vs. audiometric range after therapy. Dynamic Range measurement is a plausible simple method to check patient progress and confirm the new cochlear conditions after Laser Photo-Therapy.

- Other signs of improvement, in just about all patients treated, are:
- Remission of ears pressure. This is noticeable from the beginning or first treatment sessions.
 - Normalization of stability and balance, also in cases of neuritis.
 - Remission and tolerance of the hassle in environments of high or loud sounds
 - More than 50% of the patients referred to a change or reduction of tinnitus.
 - Patients with crisis of Tumarkin, also obtained full control.

REFERENCES

- Mi XQ, Chen JY, Liang ZJ. et al. In vitro effects of helium-neon laser irradiation on human blood: blood viscosity and deformability of erythrocytes. Photomed Laser Surg. 2004; 22:477–482. [PubMed: 15684746]
- Mi XQ, Chen JY, Cen Y, et al. A comparative study of 632.8 and 532 nm laser irradiation on some rheological factors in human blood in vitro. J Photochem Photobiol B. 2004; 74:7–12. [PubMed:15043841]
- Karu T., Mitochondrial Mechanisms of Photobiomodulation in Context of New Data About Multiple Roles of ATP. Photomedicine and Laser Surgery, Volume 28, Number 2, 2010, 159-160
- Tiina Karu. Ten Lectures on Basic Science of Laser Phototherapy. Prima Books AB. printed Sweden. 2007. ISBN 978-91-976478-0-9
- Tauber S., Lightdosimetric Quantitative Analysis of the Human Petrous Bone: Experimental Study for Laser Irradiation of the Cochlea. Lasers in Surgery and Medicine 28:18–26 (2001)
- Zazzio M. Pain threshold Improvement for chronic hyperacusis patients, a prospective clinical study. Photomed Laser Surg. 2010 Jun. 28(3):371-7
- Graffelman, J., Prósper, J., The Analysis of Audiometric Measurements before and after Low-Level Laser Therapy of Spanish Patients with Hyperacusis. Department of Statistics and Operations Research Universitat Politècnica Catalunya April 2013. Av. Diagonal 647, 08028 Barcelona, Spain., Contact email: jan.graffelman@upc.edu

Left ear Audiometry of Patient with Menière Disease



CONTACT

Joaquin Prosper
OTOCLINICA (Vestibular & Tinnitus Disorders)
Email: prosper@otoclinica.es
Phone: +34 915 648 744
Mobile: +34 616 243 654
Website: www.otoclinica.org